

Supporting Information

McGlenn et al. 10.1073/pnas.0910374106

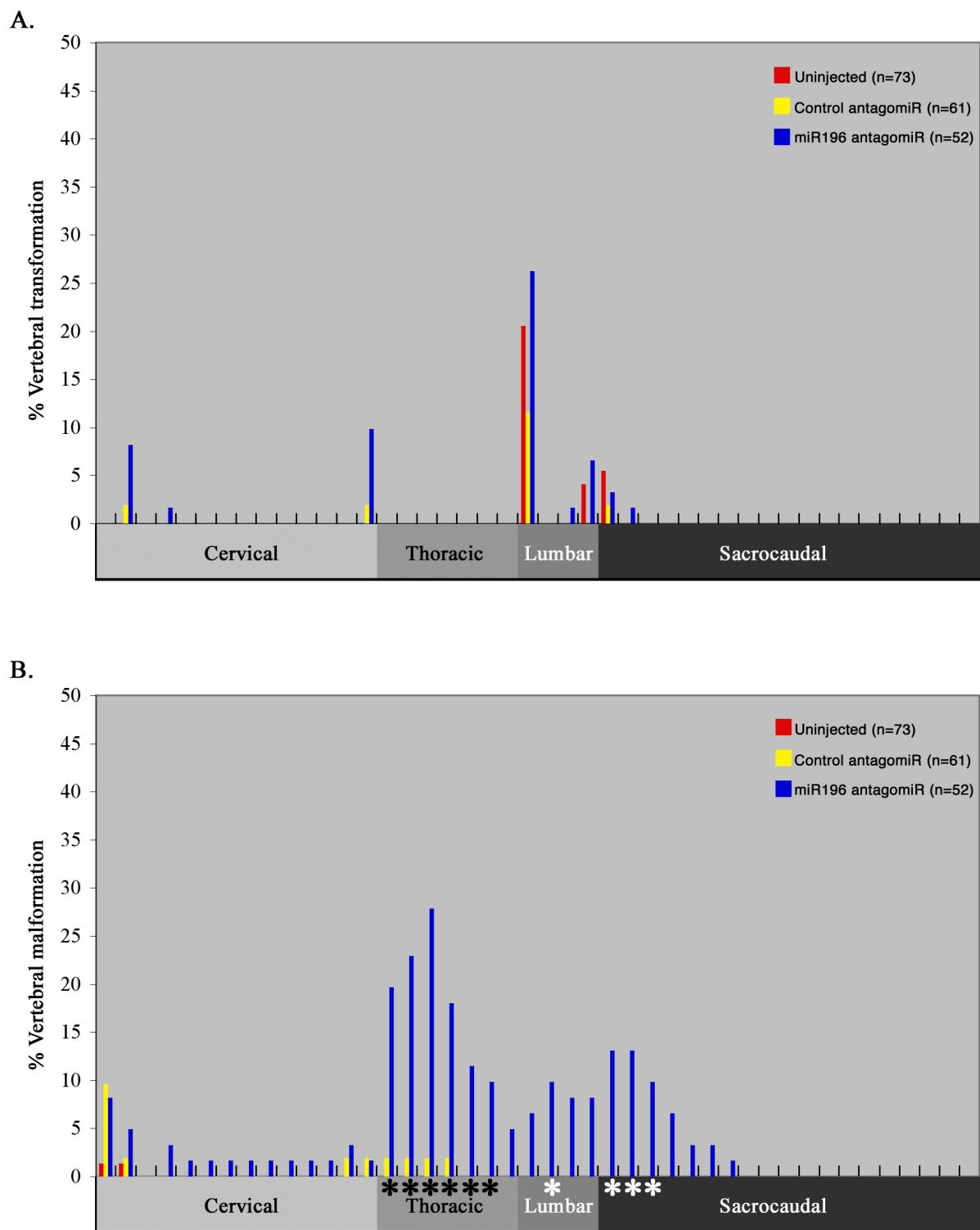


Fig. S1. Homeotic transformations and malformations of the axial skeleton observed following systemic antagomiR196 injection. Homeotic transformations (A) and vertebral malformations (B) observed for each individual vertebral segment, expressed as a percentage of total embryo number for each condition. The asterisk represents statistical significance (P value <0.05) of the frequency of defects at a given position, calculated by Fisher's Exact Test.